

# An Examination of the in Vitro Effects on Fibroblasts of Periarticular Injection Solution Applied in Total Hip and Knee Arthroplasty

Muhammed Sadik Bilgen<sup>1</sup>, Zeynep Kahveci<sup>2</sup>, Ilkin Cavusoglu<sup>2</sup>, Muren Mutlu<sup>3</sup>, Omer Faruk Bilgen<sup>3</sup>, Aysun Yilmazlar<sup>4</sup>

<sup>1</sup>Uludag University, Faculty of Medicine, Orthopaedics and Traumatology Department, Bursa, Turkey

<sup>2</sup>Uludag University, Faculty of Medicine, Histology and Embryology Department, Bursa, Turkey

<sup>3</sup>Private Medicabil Hospital, Orthopaedics and Traumatology Department, Bursa, Turkey

<sup>4</sup>Private Medicabil Hospital, Anaesthesiology and Intensive Care Department, Bursa, Turkey

## Email address:

msbilgen@superonline.com (M. S. Bilgen), zeynep2@uludag.edu.tr (Z. Kahveci), ilkin@uludag.edu.tr (I. Cavusoglu), muren.mutlu@medicabil.com (M. Mutlu), ofbilgen@gmail.com (O. F. Bilgen), aysun.yilmazlar@medicabil.com (A. Yilmazlar)

## To cite this article:

Muhammed Sadik Bilgen, Zeynep Kahveci, Ilkin Cavusoglu, Muren Mutlu, Omer Faruk Bilgen, Aysun Yilmazlar. An Examination of the in Vitro Effects on Fibroblasts of Periarticular Injection Solution Applied in Total Hip and Knee Arthroplasty. *International Journal of Anesthesia and Clinical Medicine*. Vol. 9, No. 2, 2021, pp. 28-31. doi: 10.11648/j.ijacm.20210902.12

**Received:** June 16, 2021; **Accepted:** June 29, 2021; **Published:** July 8, 2021

**Abstract:** The number of indications for total hip and knee surgery is increasing. The anesthesia and analgesia techniques are very important and effectivity on success of total hip and knee arthroplasty. Multimodal analgesia makes a great contribution to pain treatment after surgery. Periarticular injection of an analgesic solution is a component of multimodal analgesia. However, it has long been unclear whether such injections damage tissue. The fibroblasts were cultured in 5 mL of D-MEM/F-12 medium in each well of a 6-well culture dish. After 1 hour, we added 5 mL of prepared periarticular injection solution to each well of the study group. To determine the effects of the solution on the fibroblasts, we assessed viability rates at the end of 24, 48, and 72 hours. When we compared the control and the study group, we did not encounter any apoptotic or dying cells in either group, which we interpreted to mean that the periarticular injection solution did not show a lethal effect on fibroblasts. Therefore, we conducted an in vitro and electron microscope study to research this issue. We found that the number and viability of fibroblasts did not change significantly with periarticular injection and thus concluded does not cause cell damage and can safely be used.

**Keywords:** Periarticular Injection, Hip and Knee Arthroplasty, Analgesia, Fibroblast

## 1. Introduction

Multimodal analgesic regimens that target numerous pain pathways may provide the best pain management, rehabilitation, patient satisfaction, and reduce opioid use and related side effects. Periarticular injections of delayed-release local anesthetics may further enhance pain management [1].

Targeting specific sites of nociceptors may help to further decrease pain after knee and hip arthroplasties. Altering periarticular cocktail ingredients may aid in multimodal pain control with injections [2].

Periarticular injection of an analgesic solution is an

important component of multimodal analgesia in total hip and knee arthroplasty. It is prepared by adding 200 to 400 mg of 0.5% bupivacaine, 4 to 10 mg of morphine, 300 µg of epinephrine, 40 mg of methylprednisolone, and 750 mg of cefuroxime axetil to saline to create a volume of 60 mL [1–3]. Bupivacaine is used for nociceptor inhibition, morphine is used for peripheral opioid receptor inhibition, epinephrine is used for length the local anaesthetic's duration, methylprednisolone, is used for antiinflammatory effectivity and cefuroxime axetil is used for infection prophylaxis. In hip arthroplasty, the solution is injected [3] before reduction of the implant components into the anterior capsule and the other structures [4]; after reduction, into the posterior

capsule, external rotators, soft tissues in the trochanteric area, and the tensor fascia lata. In knee arthroplasty, the solution is injected [3] before reduction of the implant components into the posterior capsule [4]; after reduction, into the extensor mechanism, synovia, capsule, pes anserinus, collateral ligaments, and iliotibial band [3].

However, there are no reports in the literature showing either positive or negative effects of this injection solution at the cellular level.

Li et al, suggested that autophagosome formation was induced as a stress response mechanism after bupivacaine challenge; however, autophagosome clearance was impaired due to inadequate autophagosome-lysosome fusion [6]. Therefore, impairment of autophagosome clearance appears to be a novel mechanism underlying bupivacaine-induced myotoxicity.

Therefore, we conducted a cell culture and electron microscope study to examine in an in vitro environment the effects on fibroblasts, which are secreting and synthesizing connective-tissue fibers and ground substance and are most often found in connective tissue.

## 2. Methods

We used 3T3 rat fibroblast cells, supplied by the cell bank of Istanbul University's Faculty of Medicine Cell Culture Laboratory. The fibroblasts were kept in 25-cm<sup>2</sup> and 75-cm<sup>2</sup> flasks containing D-MEM/F-12 medium (Dulbecco's Modified Eagle Medium: Nutrient Mixture Ham's F-12 medium, Gibco Life Technologies, Grand Island, NY, USA) in an incubator (Sanyo, City Name, US State Name, Country Name) with 5% CO<sub>2</sub>, set at 95% humidity and at 37°C and passaged twice a week.

At the first stage of the study, we cultured  $2.5 \times 10^6$  3T3 fibroblasts in 5 mL of D-MEM/F-12 medium in each well of a 6-well culture dish. After 1 hour, we added 5 mL of prepared periarticular injection solution (dosage calculation is shown in Table 1) to each well of the study group. To determine the effects of the solution on the fibroblasts, we assessed viability rates using the trypan blue staining method at the end of 24, 48, and 72 hours.

**Table 1.** Calculation of the Dosage of Periarticular Injection Solution.

	Molecular Weight	Commercial Medication Concentration (mM)	Concentration in 60 mL	Volume/5 mL to Be Taken for Cell Culture
Isobaric 0.5% bupivacaine, 200 mg	288.432	17	11.3 mM	3333 µl/5 mL
Morphine sulphate, 8 mg	668.75	11.9	158 µM	66 µl/5 mL
Adrenalin, 300 mg	183.21	1.64	8 µM	25 µl/5 mL
Cefuroxime (Cefax) 750 mg	424.06	294	29 mM	500 µl/5 mL
Methylprednisolone acetate (Depo-Medrol), 40 mg	374.48	106	1.78 mM	83 µl/5 mL
Total				4007 µL total medication + 993 µL saline

At the end of the defined time periods, we evaluated the ultrastructure of the fibroblasts by using routine electron microscope processing methods at Uludag University, Histology and Embriology Department. The ultrathin sections were evaluated and photographed with a transmission electron microscope (100SX TEM, Jeol, Peabody, MA, USA).

## 3. Results

In the group to which the periarticular injection solution

was applied, the numbers of fibroblasts obtained at the end of 48 and 72 hours were approximately the same as in the first 24 hours. In the control group, the number of fibroblasts at 48 hours was 47% larger than the number obtained in the first 24 hours, and at 72 hours, the number was 7% larger than the number obtained at 48 hours.

In the group to which solution had been applied, the rates of viable fibroblasts determined with the trypan blue staining method were 96% at 24 hours, 98.2% at 48 hours, and 96.7% at 72 hours. In the control group, these rates were 95.1% at 24 hours, 98.7% at 48 hours, and 97.9% at 72 hours (Table 2).

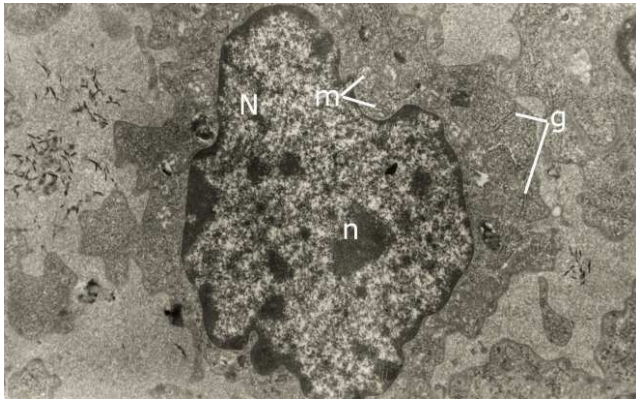
**Table 2.** Numbers of live fibroblasts and the live rates determined with the Trypan Blue staining method.

Parameters	Control	Study
Initial cell count	2 500 000	2 500 000
Cell count/live rates at 24 hours	3 680 000 / 95.1%	3 380 000 / 96%
Cell count/live rates at 48 hours	7 120 000 / 98.7%	3 030 000 / 98.2%
Cell count/live rates at 72 hours	7 733 000 / 97.9%	3 003 000 / 96.7%

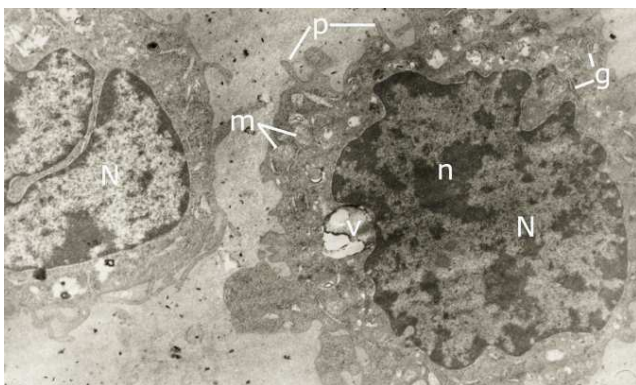
In the transmission electron microscopic examination, fibroblasts in the control group generally had a normal morphologic appearance. The nuclei were ovoid and large, containing fine chromatin and a discernible nucleolus. In the cytoplasm, we observed rough endoplasmic reticulum, Golgi complex, and mitochondria. We did not encounter any apoptotic fibroblasts in the examined sections, and we did not find any with a pathologic appearance (Figure 1).

In the study group to which the periarticular solution had been applied, the general appearance of the fibroblasts was healthy. The nuclei looked normal and had a discernible nucleolus. As the time periods extended, there was a noticeable increase in vacuoles and phagosomes, but the organelles such as rough endoplasmic reticulum, mitochondria, and Golgi complex differed and were still present in the fibroblast cytoplasm. In addition, cytoplasmic

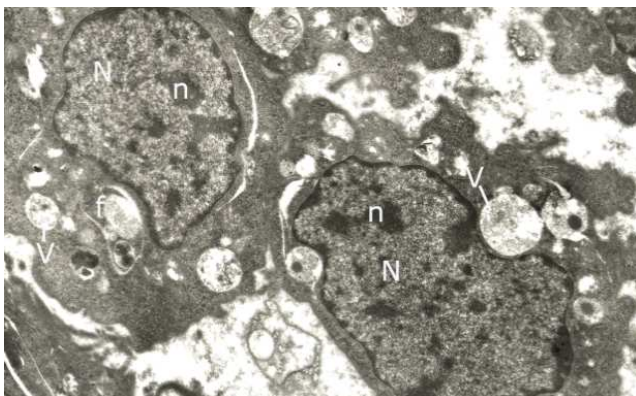
protrusions were observed, similar to pseudopods on fibroblast membranes (Figures 2 through 4). We considered these findings as evidence of an increase in phagocytic activity in the cells. When we compared the control group and the study group, we did not encounter any apoptotic or dying cells in either group, which we interpreted to mean that the periarticular injection solution did not show a lethal effect on fibroblasts.



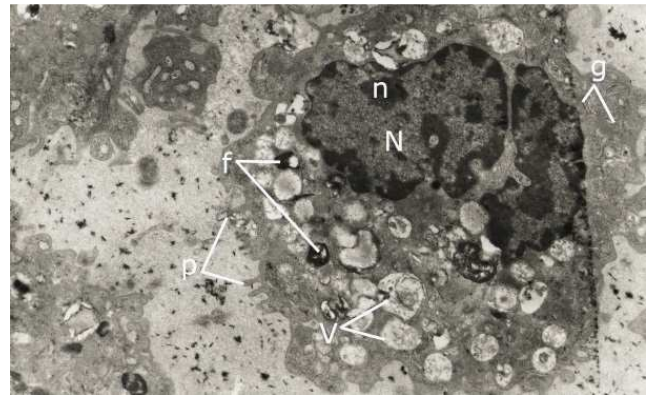
**Figure 1.** Electron microscopic image of healthy fibroblasts in the control group (original magnification x80000) (N: nucleus, n: nucleolus, m: mitochondria, g: granulated endoplasmic reticulum).



**Figure 2.** Electron microscopic image of fibroblasts in the study group 24 hours after application of the solution (original magnification x60000) (N: nucleus, n: nucleolus, m: mitochondria, g: granulated endoplasmic reticulum, p: pseudopod).



**Figure 3.** Electron microscopic image of fibroblasts in the study group 48 hours after application of the solution (original magnification x 60000) (N: nucleus, n: nucleolus, v: vacuole, f: phagosome).



**Figure 4.** Electron microscopic image of fibroblasts in the study group 72 hours after application of the solution (original magnification x 60000) (N: nucleus, n: nucleolus, g: granulated endoplasmic reticulum, v: vacuole, f: phagosome, p: pseudopod).

## 4. Discussion

In current practice, multimodal analgesia makes a great contribution to pain treatment after total hip and knee arthroplasty and thereby to the early ambulation of the patient [7-15]. The combination of epidural analgesia and a periarticular injection decreases the postoperative need for epidural analgesia, and thus the adverse effects of epidural analgesia, such as hypotension, bradycardia, and respiratory depression are avoided, as are effects that increase patients' discomfort, such as sleepiness and itching.

However, it has long been unclear whether periarticular injection is harmful to fibroblasts and the surrounding tissues. Our findings show that periarticular injection of an analgesic solution does not cause cell damage or death. Our findings of vacuolization and phagosome structures in the fibroblast cytoplasm can be interpreted as evidence that the cells remain alive and that the solution added to the environment is phagocytosed. The insignificant difference in viability rates between our control and study groups can be interpreted as evidence that the added injected solution had no effect on cell vitality.

## 5. Conclusion

Because there was no negative effect on the ultrastructure and number of live fibroblasts in the in vitro environment, it can be concluded that periarticular injection of an analgesic solution can be considered a safe component of multimodal analgesia. Future experimental studies under in vivo conditions are required to support our findings.

## Author Contributions

Design of the protocol: OFB, MSB and AY.

Data collection and analysis: ZK and IC.

All the authors contributed to writing of the manuscript.

## Conflict of Interest Statement

The authors declare that they have no competing interests.

---

## References

- [1] Elmallah RK, Chuqta M, Khlopas A, Newman JM, Stearns KL, Roche M, Kelly MA, Harwin SF, Mont MA. Pain Control in Total Knee Arthroplasty. *Knee Surg* 2018; 31 (6): 504-513.
- [2] Ross JA, Greenwood AC, Sasser P, Jiranek WA. Periarticular Injections in Knee and Hip Arthroplasty: Where and What to Inject. *J Arthroplasty* 2017; 32 (9S): S77-S80.
- [3] Parvataneni HK, Shah VP, Howard H, Cole N, Ranawat AS, Ranawat CS. Controlling pain after total hip and knee arthroplasty using a multimodal protocol with local periarticular injections: a prospective randomized study. *J Arthroplasty* 2007; 22 (6 Suppl 2): 33-8.
- [4] Maheswari AV, Blum YC, Shekhar L, Ranawat AS, Ranawat CS. Multimodal pain management after total hip and knee arthroplasty at the Ranawat Orthopaedic Center. *Clin Orthop Relat Res* 2009; 467 (6): 1418.
- [5] Parvataneni HK, Ranawat AS, Ranawat CS. The use of local periarticular injections in the management of postoperative pain after total hip and knee replacement: a multimodal approach. *Instr Course Lect* 2007; 56: 125.
- [6] Li R, Ma H, Zhang X, Li C, Xiong J, Lu T, Mao Y, Dai J, Liu L, Ding Z. Impaired autophagosome clearance contributes to local anesthetic bupivacaine-induced myotoxicity in mouse myoblasts. *Anesthesiology*. 2015 Mar; 122 (3): 595-605. doi: 10.1097/ALN.0000000000000568.
- [7] Mullaji A, Kanna R, Shetty GM, Chavda V, Singh DP. Efficacy of periarticular injection of bupivacaine, fentanyl, and methylprednisolone in total knee arthroplasty: a prospective, randomized trial. *J Arthroplasty* 2010; 25: 851-7.
- [8] Andersen KV, Nikolajsen L, Haraldsted V, Odgaard A, Soballe K. Local infiltration analgesia for total knee arthroplasty: should ketorolac be added? *Br J Anaesth* 2013; 111: 242-8.
- [9] Lamplot JD, Wagner ER, Manning DW. Multimodal pain management in total knee arthroplasty: a prospective randomized controlled trial. *J Arthroplasty* 2014; 29: 329.
- [10] Leone S, Di Cianni S, Casati A, Fanelli G. Pharmacology, toxicology, and clinical use of new long acting local anesthetics, ropivacaine and levobupivacaine. *Acta Biomed* 2008; 79: 92-105.
- [11] Ng FY, Ng JK, Chiu KY, Yan CH, Chan CW. Multimodal periarticular injection vs continuous femoral nerve block after total knee arthroplasty: a prospective, crossover, randomized clinical trial. *J Arthroplasty* 2012; 27: 1234-8.
- [12] Wu JW, Wong YC. Elective unilateral total knee replacement using continuous femoral nerve blockade versus conventional patient-controlled analgesia: perioperative patient management based on a multidisciplinary pathway. *Hong Kong Med J* 2014; 20: 45-51.
- [13] Ma HH, Chou TFA, Tsai SW, Chen CF. The efficacy of intraoperative periarticular injection in total hip arthroplasty: a systemic review and meta-analysis *BMC Musculoskeletal Disorders*. 2019; 29: 269-78.
- [14] Ban WR, Zhang EA, Lv LF, Dang XQ, Zhang C. Effects of periarticular injection on analgesic effects and NSAID use in total knee arthroplasty and total hip arthroplasty. *Clinics*. 2017; 72 (12): 729-36.
- [15] Villatte G, Engels E, Erivan R, Mulliez A, Caumon N, Boisgard S, Descamps S. Effect of local anaesthetic wound infiltration on acute pain and bleeding after primary total hip arthroplasty: the EDIPO randomised controlled study. *Int Orthop*. 2016; 40 (11): 2255-60.