

Case Report

Treatment of Postoperative Sore Throat with Ultrasound-guided Internal Branch of Superior Laryngeal Nerve Block: A Report of Three Cases

Meirong Wang, Zhipeng Li, Huibi Ouyang, Chuiliang Liu*

Department of Anesthesiology, Chancheng District Central Hospital, Foshan, China

Email address:

wangmrong1217@163.com (Meirong Wang), 545076940@qq.com (Zhipeng Li), 592627767@163.com (Huibi Ouyang), 476140516@qq.com (Chuiliang Liu)

*Corresponding author

To cite this article:

Meirong Wang, Zhipeng Li, Huibi Ouyang, Chuiliang Liu. Treatment of Postoperative Sore Throat with Ultrasound-guided Internal Branch of Superior Laryngeal Nerve Block: A Report of Three Cases. *International Journal of Anesthesia and Clinical Medicine*. Vol. 8, No. 1, 2020, pp. 14-17. doi: 10.11648/j.ijacm.20200801.14

Received: February 13, 2020; Accepted: February 25, 2020; Published: March 17, 2020

Abstract: Background Postoperative sore throat (POST) is a common problem following extubation after general anesthesia (GA). Severe POST leads to dissatisfaction and discomfort for a longer period, are resistant to current medical treatment. Method POST was measured after extubation 30 min, 2 h, 4 h, 6 h and 24 h. We present three cases of severe hoarseness or aphonia after extubation. A 8–13 MHz high frequency linear probe ultrasound transducer was used to visualize the internal branch of superior laryngeal nerve block (ibSLNB), which through thyrohyoid membrane between hyoid bone and thyroid cartilage. By out-plane technique, 2 mL of 2% lidocaine was injected around ibSLNB on each side. Result The three cases with severe POST was successfully treated with ultrasound-guided bilateral ibSLNB within 5 min, and their voice rapidly became louder and clearer. POST was significantly disappeared for 2-4 hours, and subsequently the resurfaced throat pain was milder, only needed or no anti-inflammatory drugs. No choking or aspiration was observed after ibSLNB when they were asked to swallow 20 ml of liquid 2 h post-operation. No postoperative laryngospasm or vomiting were recorded. Conclusion The ultrasound-guided bilateral ibSLNB may be a valid alternative to drugs, especially in serious acute POST after extubation.

Keywords: Postoperative Sore Throat, Ultrasound-guided, Superior Laryngeal Nerve Block, Extubation

1. Introduction

Postoperative sore throat (POST) has a reported incidence of up to 57.5% following general anesthesia (GA), and varies between 20–74% after tracheal intubation [1-4]. Several factors contribute to POST, and tracheal intubation is associated with a greater risk [2-3, 5]. POST leads to dissatisfaction and discomfort after extubation. It was ranked as the second most common minor adverse event during GA recovery [1]. Symptoms typically last from a few hours to two days, but can last for many weeks in more severe cases,

and are resistant to current medical treatment. Numerous techniques can reduce the incidence of POST.

2. Method

POST was measured by a 4 grade scale (Table 1). We present three cases with severe hoarseness or aphonia (Table 2). These cases were successfully treated by ultrasound-guided bilateral internal branch of superior laryngeal nerve block (ibSLNB) after extubation (Figure 1).

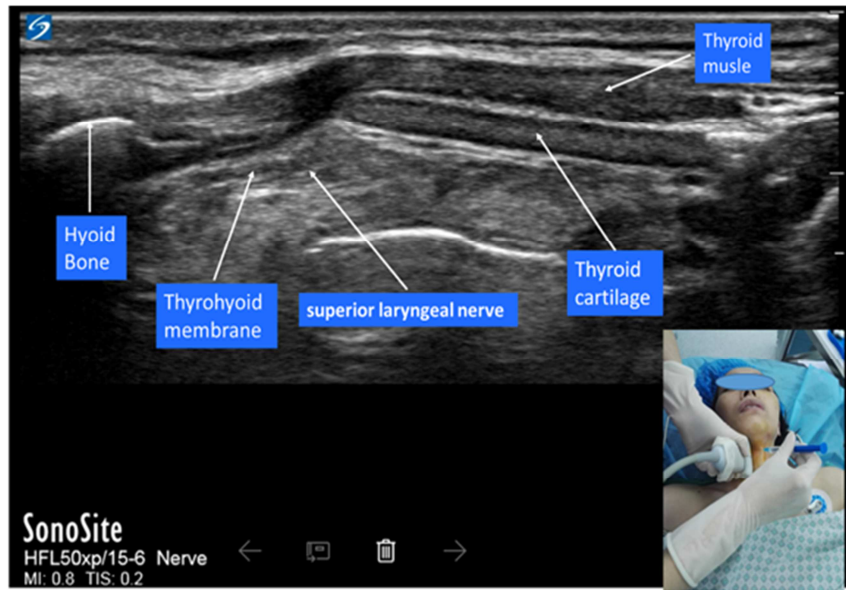


Figure 1. Ultrasound-guided bilateral internal branch of superior laryngeal nerve block. The image of the hyoid bone, thyroid cartilage, thyrohyoid membrane and superior laryngeal nerve (out-plane technique before injection).

Table 1. Scoring system for severity of sore throat [6] and hoarseness [7].

Grade Score	Sore throat severity	Hoarseness severity
Grade 0	No sore throat	None
Grade 1	Mild (complained of sore throat only upon enquiry)	Noted by the patient
Grade 2	Moderate (complained of sore throat on his/her own)	Obvious to the observer
Grade 3	Severe (severe pain associated with marked change in voice)	Aphonia

Table 2. Basic information of the patients.

Index	Case 1	Case 2	Case 3
Age (y)	28	33	51
Weight (kg)	47	74	60
Gender	female	male	female
Special history	no	no	hypertension
Surgery	laparoscopic ovarian cyst removal	bilateral tonsillectomy	microlumbar discectomy
Duration of intubation	40 min	30 min	60 min

2.1. Case 1

A 28-year-old woman underwent a 70-minute laparoscopic surgery for ovarian cyst removal under GA with endotracheal intubation. She had no history of special disease. Immediately after extubation, she complained of throat pain and hoarseness. The symptoms worsened after intravenous injection of anti-inflammatory medication. She could barely speak and her voice was barely heard. She described the feeling of a “lump” in her throat that prevented her from speaking or swallowing saliva because of sore throat. She developed severe aphonia 30 min after extubation. The otolaryngologist and anesthesiologist reassured her that no mandibular dislocation had occurred. The sore throat and hoarseness severity was defined as Grade 3 (Table 1). She consented to ultrasound-guided bilateral ibSLNB with 2 mL of 2% lidocaine on each side. The throat pain disappeared within 5 min. She could speak and be heard in low whisper. The sore throat severity was reassessed as Grade 0 at 2 h and 4 h post-ibSLNB (Table 3).

2.2. Case 2

A 33-year-old male underwent bilateral tonsillectomy under GA with intubation airway management. He was, otherwise, fit and well. The 30-minute operation was uneventful, but immediately after extubation in the recovery room, the patient complained of severe sore throat and hoarseness. The symptoms deteriorated after aerosol inhalation of 1 mg budesonide combined with 40 mg lidocaine and progressed to almost complete aphonia 30 min later. He was unable to drink water because of discomfort and pain. The sore throat and hoarseness severity was defined as Grade 3 (Table 3) and he requested emergency treatment. The anesthetist suggested ultrasound-guided bilateral ibSLNB, to which the patient consented, and 2 mL of 2% lidocaine was injected on each side. The patient’s symptoms significantly and rapidly improved, and his voice became louder and clearer. The potency lasted for the next 3 hours and the POST almost disappeared (Table 3). No choking or aspiration was observed after ibSLNB when the patient was

asked to swallow 20 ml of liquid 2 h post-operation. No postoperative laryngospasm or vomiting were recorded. The sore throat symptom resurfaced after 3 h, but was milder than before and only needed some anti-inflammatory drugs.

2.3. Case 3

A 51-year-old female, with a history of hypertension, was surgically treated for lumbar central disc extrusion under GA. She complained of severe sore throat and dysphagia 30 min after extubation. Due to inadequate airway evaluation, the patient was re-intubated and a blood-stained tracheal tube was detected on extubation. Based on the previous two cases, the anesthesiologist decided to immediately perform ibSLNB

(2 ml of 2% lidocaine per side). The sore throat and hoarseness severity degree declined sharply (Table 3). Dexamethasone 0.1 mg/kg combined with ketorolac 0.5 mg/kg was also injected before the patient left the recovery room. The symptoms significantly improved in the next 24 hours.

3. Result

POST was measured after extubation 30 min, 2 h, 4 h, 6 h and 24 h (Table 3). Although the symptoms were intense after extubation 30 min, ibSLNB was very effective and cleared most of the symptoms in 2-4 hours.

Table 3. Sore throat and hoarseness severity grade after extubation.

		30min	2h	4h	6h	24h
Case 1	Sore throat severity grade	3	0	0	1	0
	Hoarseness severity grade	3	1	1	1	1
Case 2	Sore throat severity grade	3	0	1	2	0
	Hoarseness severity grade	3	1	1	1	1
Case 3	Sore throat severity grade	3	0	0	0	0
	Hoarseness severity grade	2	2	1	1	0

4. Discussion

Postoperative sore throat (POST) including sore throat, hoarseness and dysphagia, is a common and potentially dangerous complication following general anesthesia (GA) with endotracheal intubation. Tracheal intubation is associated with a greater risk of POST than a supraglottic airway device or a face mask [1-4, 8]. One of the major causes of POST is trauma to the airway mucosa during airway management and the symptoms may be caused by immediate injury and hematoma to the laryngeal area by the insertion of tube or irritation to the laryngotracheal mucosa [3, 4, 8, 9]. Several drugs can prevent or reduce the incidence of POST, such as lidocaine (intravenous injection, aerosol spray, gel, aerosol inhalation), steroids (intravenous injection, aerosol inhalation), non-steroidal anti-inflammatory drugs (NSAIDs) and intravenous N-methyl-D-aspartate (NMDA) receptor antagonists (magnesium, ketamine), liquorice, azulene, etc [5, 9-12].

Several reports indicated that ultrasound-guided bilateral internal branch of superior laryngeal nerve block (ibSLNB) after GA was associated with better intubation conditions and recovery profile in the form of improved postoperative cough and sore throat during endotracheal surgeries [13-15]. Patients who received bilateral ibSLNB showed significantly lower incidence of POST 1-4 h post-operation [13]. The three case reports presented here also indicated that ultrasound-guided bilateral ibSLNB helps in reducing acute serious POST, but the effect decreases after 4 h, which is related to the pharmacological properties of local anesthesia. A previous study compared lidocaine to ropivacaine in peripheral nerve block in pediatric patients, and found that the duration of lidocaine was 137 minutes, which was less than that of ropivacaine

(337 minutes) [16]. Hence, adrenaline or ropivacaine may prolong the duration of effect. Our case reports demonstrated that the symptoms were milder in the next 20 hours. POST peaks in the early postoperative period at 2-6 hours after extubation [17, 18].

ibSLNB is an airway anesthesia technique that can paralyze the lingual radix, epiglottis and cricothyroid muscles, and is thus expected to suppress the gag and cough reflexes [19]. The possibility of pulmonary aspiration of gastric contents after ibSLNB is a concern especially during extubation. In this study, no postoperative nausea, vomiting, choking, aspiration or other adverse effects related to superior laryngeal nerve block were found when the patients were asked to swallow liquid 2 h post-operation. Several factors contributed this outcome: (1) improvements in ultrasound technology have made it possible to obtain high-resolution images of the superior laryngeal nerve; (2) several precautions were taken such as preoperative fasting for at least 8 h, premedication with antiemetic and H2 blocker, ibSLNB was performed while patients were fully awake and no oral intake was allowed till 2 h after ibSLNB when the swallowing reflex was assessed.

5. Conclusion

These case reports showed that ultrasound-guided ibSLNB is an effective and safe treatment for serious acute POST after extubation. Further study is needed to evaluate the efficacy of chronic treatment of POST.

Authors' Contributions

All of the authors conducted the study with the supervision of Prof. Liu.

Declaration of Conflicting Interests

The authors declared no potential conflicts of interest with respect to the research, authorship, and/or publication of this article.

Ethical Approval

For all of three cases, informed consent was obtained.

References

- [1] Lee J Y, Sim W S, Kim E S, et al. Incidence and risk factors of postoperative sore throat after endotracheal intubation in Korean patients. *J Int Med Res*, 2017, 45 (2): 744-752.
- [2] Lehmann M, Monte K, Barach P, et al. Postoperative patient complaints: a prospective interview study of 12, 276 patients. *J Clin Anesth*, 2010, 22 (1): 13-21.
- [3] Aqil M, Khan MU, Mansoor S, et al. Incidence and severity of postoperative sore throat: a randomized comparison of Glidescope with Macintosh laryngoscope. *BMC Anesthesiol*, 2017, 17 (1): 127-134.
- [4] Biro P, Seifert B, Pasch T. Complaints of sore throat after tracheal intubation: a prospective evaluation. *Eur J Anaesthesiol*, 2005, 22: 307-311.
- [5] El-Boghdadly K, Bailey C R, Wiles M D. Postoperative sore throat: a systematic review. *Anaesthesia*, 2016, 71 (6): 706-717.
- [6] Borazan H, Kececioglu A, Okesli S, et al. Oral magnesium lozenge reduces postoperative sore throat: A randomized, prospective, placebo-controlled study. *Anesthesiology*, 2012, 117: 512-518.
- [7] Honarmand A, Safavi M. Bclomethasone inhaler versus intravenous lidocaine in the prevention of postoperative airway and throat complaints: a randomized controlled trial. *Ann Saudi Med*, 2008; 28 (1): 11-16.
- [8] Jaensson M, Gupta A, Nilsson U G. Risk factors for development of postoperative sore throat and hoarseness after endotracheal intubation in women: a secondary analysis. *Aana J*, 2012, 80 (4 Suppl): 67-73.
- [9] Chang JE, Min SW, Kim CS, et al. Effect of prophylactic benzydamine hydrochloride on postoperative sore throat and hoarseness after tracheal intubation using a double-lumen endobronchial tube: a randomized controlled trial. *Can J Anaesth*, 2015, 62 (10): 1097-1103.
- [10] Liu X R, Zhan D X. Effect of hydrocortisone plus parecoxib sodium on preventing postoperative sore throat after tracheal intubation with a double-lumen endobronchial tube. *J Clin Anesth*, 2013, 29 (8): 746-748.
- [11] Kalil D M, Silvestro L S, Austin P N. Novel preoperative pharmacologic methods of preventing postoperative sore throat due to tracheal intubation. *Aana Journal*, 2014, 82 (3): 188-197.
- [12] Kusunoki T, Sawai T, Komasa N, et al. Correlation between extraction force during tracheal intubation stylet removal and postoperative sore throat. *J Clin Anesth*, 2016, 33: 37-40.
- [13] Ahmed A, Saad D, Youness A R. Superior laryngeal nerve block as an adjuvant to general anesthesia during endoscopic laryngeal surgeries: A randomized controlled trial. *Egy J Anaesth*, 2015, 31 (2): 167-174.
- [14] Manikandan S, Neema PK, Rathod RC. Ultrasound-guided bilateral superior laryngeal nerve block to aid awake endotracheal intubation in a patient with cervical spine disease for emergency surgery. *Anaesth Intensive Care*, 2010, 38 (5): 946-948.
- [15] Iida T, Suzuki A, Kunisawa T, et al. Ultrasound-guided superior laryngeal nerve block and translaryngeal block for awake tracheal intubation in a patient with laryngeal abscess. *J Anesthesia*, 2013, 27 (2): 309-310.
- [16] Felfernig M, Marhofer P, Weintraud M, et al. Use of ropivacaine and lidocaine for axillary plexus blockade. *Afr J Paediatr Surg*, 2010, 7 (2): 101-104.
- [17] Jaensson M, Olowsson LL, Nilsson U. Endotracheal tube size and sore throat following surgery: a randomized-controlled study. *Acta Anaesthesiol Scand*, 2010, 54 (2): 147-153.
- [18] Hung NK, Wu CT, Chan SM, et al. Effect on postoperative sore throat of spraying the endotracheal tube cuff with benzydamine hydrochloride, 10% lidocaine, and 2% lidocaine. *Anesth Analg*, 2010, 111 (4): 882-886.
- [19] Kumar A, Sinha C, Kumar A, et al. Transverse approach for ultrasound-guided superior laryngeal nerve block for awake fiberoptic intubation. *Saudi J Anaesth*, 2017, 11 (3): 73-74.